



Contents lists available at ScienceDirect

## Journal of Cranio-Maxillo-Facial Surgery

journal homepage: [www.jcmfs.com](http://www.jcmfs.com)

# A clinical and radiographic case series of implants placed with the simplified minimally invasive antral membrane elevation technique in the posterior maxilla



Udatta Kher<sup>a</sup>, Andreas L. Ioannou<sup>b,\*</sup>, Tarun Kumar<sup>c</sup>, Kostantinos Siormpas<sup>d</sup>,  
Miltiades E. Mitsias<sup>e</sup>, Ziv Mazor<sup>f</sup>, Georgios A. Kotsakis<sup>b</sup>

<sup>a</sup> Private Practice, Mumbai, India

<sup>b</sup> Advanced Education Program in Periodontology, University of Minnesota, United States

<sup>c</sup> Division of Periodontology, Bapuji Dental College & Hospital, Davangere, India

<sup>d</sup> Private Practice, Larissa, Greece

<sup>e</sup> Department of Periodontology & Implant Dentistry, New University College of Dentistry, NY, United States

<sup>f</sup> Private Practice, Ra'anana, Israel

## ARTICLE INFO

### Article history:

Paper received 2 March 2014

Accepted 15 August 2014

Available online 27 August 2014

### Keywords:

Maxilla/surgery

Maxillary sinus/surgery

Sinus floor augmentation/methods

Surgical procedures

Minimally invasive

Putty bone substitute

## ABSTRACT

The aim of the present case series was to evaluate a simplified minimally invasive transalveolar sinus elevation technique utilizing calcium phosphosilicate (CPS) putty for hydraulic sinus membrane elevation. The simplified minimally invasive antral membrane elevation technique is based on the application of hydraulic pressure via a viscous bone graft that acts as an incompressible fluid.

In this retrospective study, 21 patients (mean age:  $48.5 \pm 12$  years) consecutively treated with the simplified minimally invasive transalveolar sinus elevation technique were evaluated. 28 tapered implants were placed in posterior maxillary sites with less than 6 mm of residual bone height as determined radiographically on cone beam volumetric tomographs. No sinus membrane perforations were noted and none of the patients complained of symptoms of sinusitis post-operatively (0%). The mean gain in bone height post-operatively was  $10.31 \pm 2.46$  mm ( $p < 0.001$ ). All implants successfully integrated (100% success rate) and were loaded with cement-retained prostheses.

The proposed technique is a simple, efficacious, minimally invasive approach for sinus elevation that can be recommended for sites with at least 3 mm of residual height.

© 2014 European Association for Cranio-Maxillo-Facial Surgery. Published by Elsevier Ltd. All rights reserved.

## 1. Introduction

Dental implant therapy has revolutionized the rehabilitation of both the form and the function of missing teeth. In contemporary dental practice, implant dentistry is recognized as the “golden standard” for the rehabilitation of edentulous sites (Scheuber et al., 2012). Patients' demands frequently dictate minimally invasive surgery and timely delivery of restoration (Hartlev et al., 2013; Nickenig et al., 2014). This dual goal can be readily delivered by concepts such as immediate implant placement, or non-submerged implant placement in sites with adequate bone volume post-

extraction, but is unrealistic for sites where anatomic limitations require more involved procedures (Hartlev et al., 2013). One such case is the edentulous posterior maxilla.

Following extraction of teeth in the maxillary posterior region, pneumatization of the maxillary sinus frequently occurs (Mazor et al., 1999; Rothamel et al., 2007). Depending on the degree of pneumatization in conjunction with the amount of coexisting ridge resorption in an apical-coronal direction, different surgical methods are employed for sinus lift surgery (Summers, 1994; Mazor et al., 1999; Nkenke et al., 2002; Kfir et al. 2006). Traditionally, indirect, or transalveolar sinus floor elevation techniques are utilized when less than 5 mm of gain in bone height are sought, while more aggressive direct, or lateral-window approaches are utilized in more advanced cases (Engelke and Deckwer, 1997).

Direct sinus augmentation techniques have been shown to yield very favorable outcomes in regards to bone regeneration in the

\* Corresponding author. Advanced Education Program in Periodontology, University of Minnesota, 515 Delaware Street SE, Minneapolis, MN 55455, United States. Tel.: +1 651 395 9200.

E-mail address: [ioann005@umn.edu](mailto:ioann005@umn.edu) (A.L. Ioannou).

sinus as well as very good success rates for implants placed in grafted bone (Mazor et al., 1999; Galindo-Moreno et al., 2008). One of the major drawbacks associated with this type of technique is patient satisfaction. Not only do patients undergo a more involved procedure that has greater morbidity than conventional implant placement, but they usually have to wait for several months prior to having their chief concern addressed, restoration of their functional ability.

In a hypothetical case of ridge atrophy with coexisting pneumatization of the sinus it is not infrequent for less than 5 mm of residual bone height to remain in the posterior maxilla. In such a case a patient would routinely undergo direct sinus augmentation followed by implant placement approximately 6–9 months later, they would finally have the implant restored after 3–4 months of healing, giving a total treatment time of approximately 1 year. It is only reasonable that this estimated waiting time would seem protracted to the majority of patients. In order to address this concern there are recent reports in the literature showing that the controlled elevation of the sinus floor using hydraulic pressure may extend the indications for transalveolar sinus augmentation techniques and reduce treatment time for patients (Kfir et al., 2007, 2009a, 2011). Utilizing the minimally invasive antral membrane elevation technique, Kfir et al. (2006) were successful in achieving up to, or even beyond, 10 mm of gain in vertical bone height in a series of published reports (Kfir et al., 2007, 2009b; 2011, 2012). The rationale behind the use of a balloon is the even distribution of hydraulic pressure at the membrane–bone interface that results in atraumatic and safe elevation of the schneiderian membrane. Although efficacious, this technique has not become the standard method for sinus elevation surgical procedures, possibly because of the need to purchase specialized equipment and for specific training.

The number of different surgical techniques for sinus augmentation is only surpassed by the number of biomaterials that have been used to overcome the challenge of insufficient vertical bone height in the posterior maxilla (Galindo-Moreno et al., 2008; Dahlin and Johansson, 2011). Various bone-grafting materials are frequently used in sinus lift procedures, including autogenous bone, allografts, xenogeneic bone, and alloplastic bone substitutes (Del Fabbro et al., 2004; Galindo-Moreno et al., 2008; Sununliganon et al. 2014; Xuan et al. 2014). Recent data have shown that bone substitutes displaying a putty-like consistency can present a valuable alternative in bone-grafting procedures (Vance et al., 2004; Mahesh et al., 2012; Kotsakis et al., 2012, 2014a). The handling characteristics of putty bone substitutes have expanded the available array of treatment options for bone grafting in narrow spaces, and their viscoelastic properties may be exploited to increase the safety and predictability of sinus lift procedures.

The aim of the present case series was to evaluate a minimally invasive transalveolar sinus elevation technique utilizing calcium phosphosilicate (CPS) putty for hydraulic sinus membrane elevation.

## 2. Materials and methods

### 2.1. Patient selection

In this retrospective study, 21 patients consecutively treated in a dental clinic with a simplified, minimally invasive technique for transalveolar sinus elevation were evaluated. Data related to age, sex, implant location, intra-operative or post-operative complications, implant stability, implant success and radiographic bone changes were recorded for all patients. Patients with treatment plans for sinus elevation surgery with simultaneous implant


placement were included in this study. A minimum of 2 mm of bone height from the crest of the ridge to the floor of the sinus, and 5 mm of minimum bone width were set as inclusion criteria. In addition, patients had to be healthy, non-smokers, with no history of acute sinusitis or sinus pathology. Patients with asymptomatic mild thickening of the sinus mucosa were included. Exclusion criteria included history of previous maxillary sinus surgery, chronic intake of any medication that affects bone healing (chronic steroid regimen, oral or IV bisphosphonates, etc.), active periodontal disease, or periapical pathology of the adjacent teeth.

All patients were evaluated preoperatively for the need for sinus augmentation via cone beam tomography scans (CBCTs). The indications for the procedure and possible complications were reviewed with the patients and all patients agreed to proceed and signed a consent form.

### 2.2. Surgical technique and follow-up

Patients were treated under local anesthesia and were pre-medicated with a loading dose of amoxicillin/clavulanate potassium administered 1 h prior to the surgical appointment (875 mg/125 mg). Transcrestal sinus floor elevations were performed using a modification of the Summer's technique (Summers, 1994). The pre-operative height of the residual ridge was assessed radiographically by an experienced implant surgeon (Fig. 1). Local anesthesia was administered using 2% lidocaine with 1:100,000 epinephrine to aid hemostasis of the area. Full thickness mucoperiosteal flaps were elevated in the posterior maxilla in order to gain access to the alveolar crest (Fig. 2A). An osteotomy was initiated at the ridge crest using a 2.0 mm pilot drill. The drill was stopped 1 mm short of the estimated height of the sinus floor. A periapical X-ray was obtained to verify the exact position of the drill in proximity to the sinus floor. The osteotomy was further widened using the drilling sequence recommended by the implant manufacturer (Tapered Internal, BioHorizons, Birmingham, AL, USA). A small quantity of approximately 0.2 cm<sup>3</sup> of CPS putty (NovaBone Dental Putty, NovaBone Products, Alachua, FL, USA) was delivered in the osteotomy via a narrow-tipped cartridge delivery system to act as a cushion prior to tapping the sinus floor, and a 3 mm concave osteotome with depth markings and a mallet were used to carefully fracture the floor of the sinus (Fig. 2B,C). Care was taken not to push the osteotome into the sinus cavity to avoid inadvertent perforation of the sinus lining. Following the green-stick fracture of the floor of the sinus, the bone substitute was directly injected into the prepared sinus cavity via the cartridge delivery system. The cartridge tip fitted tightly in the osteotomy and allowed the insertion pressure due to injection of the graft to be delivered directly to the fractured inferior border of the sinus floor. 0.5 cm<sup>3</sup> of CPS putty was carefully injected into the osteotomy (Fig. 3). The hydrostatic pressure exerted by the putty resulted in an atraumatic elevation of the sinus floor. CPS putty was added in increments until adequate elevation of the schneiderian membrane was seen on intra-operative radiographs. An appropriately sized implant was placed at the level of the osseous crest using a manual torque wrench for enhanced tactile sensation (Fig. 2D,E). The implants were initially engaged into the remaining native bone at the crest of the ridge and then slowly twisted in to engage in the viscous CPS putty at the apical aspect of the osteotomy. Cover screws were placed and primary flap closure was achieved utilizing a single interrupted suturing technique.

Postoperative instructions included oral administration of amoxicillin/clavulanate potassium (500 mg/125 mg three times a day) and ibuprofen (400 mg four times a day) for the first week



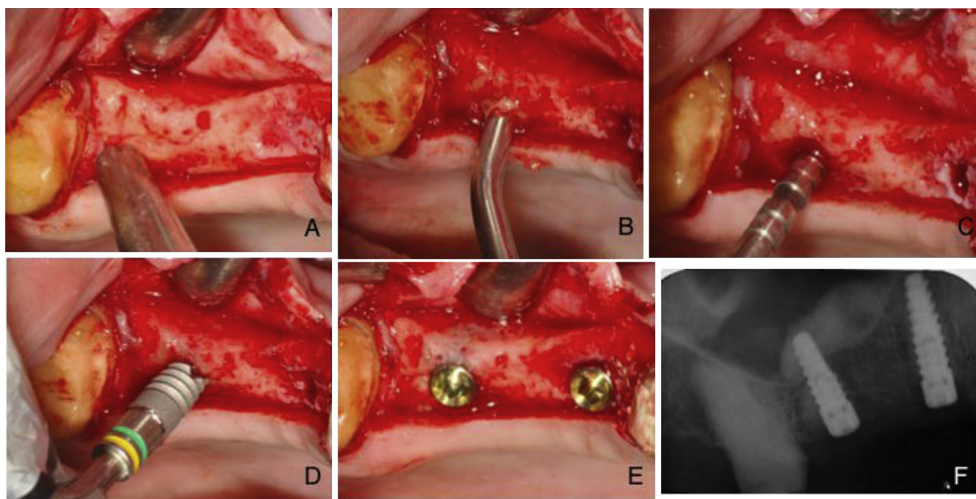
**Fig. 1.** Pre-operative assessment of the cross-sectional radiographic image revealed less than 6 mm of preoperative height on the edentulous site.

post-operatively. Chlorhexidine rinses were prescribed twice daily for 2 weeks. The patients were instructed to limit themselves to a soft diet for the first 2 weeks after surgery.


Patients were followed-up at 24 h, 10 days and 3 months after the surgery for post-surgical evaluation. Second stage surgery was scheduled at 3–5 months post-sinus lift. During the implant uncover appointment a periapical radiograph was taken to evaluate the amount of vertical bone height gain and assess radiographic signs of implant integration (Figs. 2F, 4, 5). Radiographic measurements of bone height from the crest to the floor of the sinus were calculated twice by the same examiner at two different time intervals and the means of both measurements were reported. The measurements included the scaling of the measured gain in vertical bone height based on the radiographic magnification of the implant to reduce any bias associated with possible elongation of the periapical radiographs. Specialized imaging software was used

for the above measurements (Image J, National Institutes of Health, Bethesda, Maryland, USA).

All patients were followed-up and assessed for implant survival and sinus complications on an individualized recall basis. Patients were urged to contact the implant surgeon if any complication arose between the recall appointments. Implant success was evaluated clinically according to the criteria of Cochran et al., 2002. Briefly, the examination consisted of clinical detection of implant mobility with the application of horizontal jiggling forces with the rear end of two periodontal probes. Assessment of the peri-implant tissues was performed visually for signs of erythema and/or edema and by palpation of the tissues surrounding the implant area. Additionally, periapical radiographs were obtained to ascertain the absence of a continuous radiolucency around the implant. Patients were also interviewed for subjective symptoms and evaluation of pain (Cochran et al., 2002).



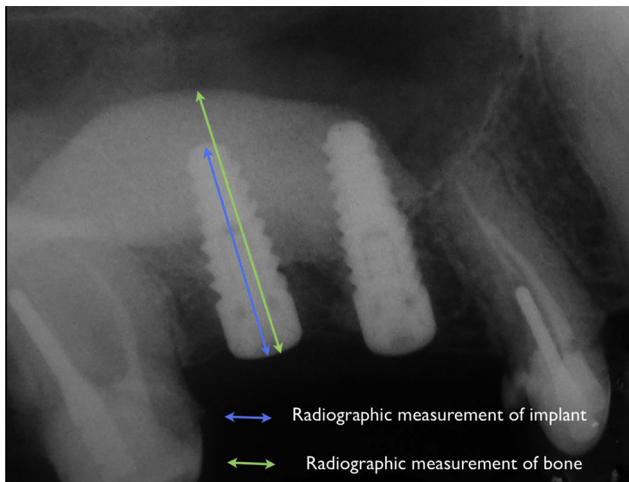
**Fig. 2.** (A) Intraoperative view of the residual ridge prior to initiation of the osteotomy; (B) the tip of the cartridge inserted into the osteotomy site; (C) application of the osteotome to produce the required elevation of the sinus floor; (D) implant placement; (E) implants placed at the level of the osseous crest; (F) postoperative radiograph showing significant elevation of the sinus floor. Note the even fill of the sinus antrum by the flow of the viscous putty.



**Fig. 3.** Note the narrow tip of the delivery system that allows intimate contact of the cartridge with the walls of the osteotomy.

### 2.3. Statistical analysis

Patient characteristics and implant success were presented descriptively. The gain in bone height post-sinus surgery was assessed with a Wilcoxon signed-rank test. The alpha level was set at  $\alpha = 0.05$ . Calculations were performed with statistical software, R



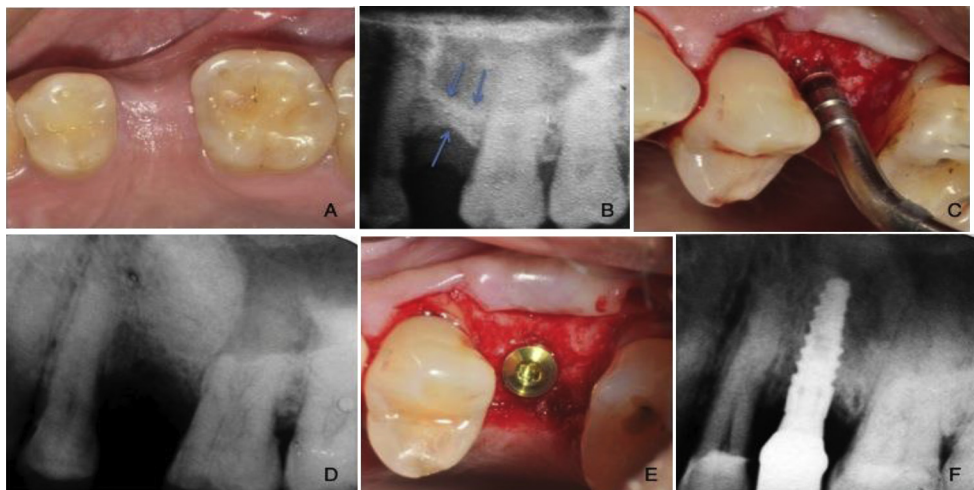
**Fig. 4.** Description of the radiographic assessment technique utilizing the known implant length as reference for accuracy of measurements.

version 3.0.1, 2013 (2013-05-16, The R Foundation for Statistical Computing, Vienna, Austria).

### 3. Results

A total of 29 implants (Tapered Internal, BioHorizons, Birmingham, AL, USA) were placed in 21 consecutively treated patients with the simplified minimally invasive transalveolar sinus elevation technique. The average patient age was  $48.5 \pm 12$  years, and 9 patients were female. None of the patients were smokers. The record of adverse events included mild to moderate postoperative edema for the first two or three postoperative days in most patients, and flap dehiscence in one patient that was caused by trauma during mastication. No reports of hematoma, severe pain, or paroxysmal vertigo were noted in the present case series. The sinus elevation was combined with CPS putty in all cases. No sinus membrane perforations were noted and none of the patients complained of symptoms of sinusitis post-operatively (0%). The mean preoperative bone height was  $4.34 \pm 1.16$  mm, while a significant gain of  $10.31 \pm 2.46$  mm was noted post-operatively ( $p < 0.001$ ) (Table 1).

Of the 29 implants placed, five were placed in 2nd premolar sites, 19 in 1st molar sites and five in 2nd molar sites. 28 of the 29 implants were placed simultaneously with the transalveolar sinus elevation with good to optimal primary implant stability in sites with residual bone height ranging from 2.8 mm to 6.5 mm. The remaining implant was placed after 6 months of healing due to the poor bone quality at the site. The residual bone height during the sinus augmentation surgery was 2.5 mm and the bone quality was deemed as poor (class IV) during implant site preparation, thus implant placement was aborted and the osteotomy was filled with CPS putty after elevation of the sinus to 13.5 mm. After 6 months of healing the site was re-entered and the implant was successfully placed with adequate primary stability. The implant was functionally loaded after 4 months of healing and remained successful throughout the follow-up period. Due to delayed implant placement this fixture was excluded from the analysis. All implants placed in this case series were left to heal for 4–5 months after implant placement and were then loaded with cement-retained prostheses. All of the simultaneously placed implants (28/28) were clinically stable and had no signs of peri-implant disease during a follow-up period of at least 1 year post-placement (minimum of 9 months post-loading) (100% success rate).



**Fig. 5.** (A) Clinical photo prior to treatment; (B) preoperative radiograph; (C) utilizing the osteotomy approach; (D) postoperative radiograph; (E) implant placed at the level of the osseous crest; (F) postoperative radiograph showing final prostheses.

**Table 1**  
Increase in vertical bone height post-surgery.

Pre-operative bone height	4.34 ± 1.16
Post-operative bone height	14.65 ± 2.17
Difference	10.31 ± 2.46*

\*Highly statistically significant ( $p < 0.001$ ).

#### 4. Discussion

The use of the minimally invasive antral membrane elevation technique has a well-documented history of success in achieving significant elevation of the sinus floor while sparing the need for more invasive direct sinus augmentation approaches (Kfir et al., 2006, 2007, 2009a, 2009b). Implant placement simultaneously with this technique is highly predictable and yields success rates ranging from 95.2% to 100% for 6–18 months of follow-up (Kfir et al., 2009b, 2011; Mazor et al., 2011). These results are comparable, yet slightly better than those reported in a large-scale survival analysis of implants placed with the osteotome technique for indirect sinus lift (Ferrigno et al., 2006). When comparing these results it should be noted that the latter study reports survival rates of up to 12 years of function, which may partially explain the difference in outcomes (Ferrigno et al., 2006).

Results from the work of Kfir et al. (2007, 2009a), and Mazor et al. (2011, 2013) are also well within the range of 92.7–96.9% survival reported by a systematic review for sinus lift using the transalveolar approach (Del Fabbro et al., 2012). In this review it was concluded that implants placed in sites with remaining bone height less than 5 mm have a reduced overall survival rate (Del Fabbro et al., 2012). Even though in most published cases, the minimally invasive antral membrane elevation technique has been utilized in cases with less than 5 mm of residual bone height, survival of implants placed with this technique is very high, reaching up to 100% for 18 months of follow-up (Mazor et al., 2011).

The most significant benefit from the use of this technique is that it can achieve a gain in bone height comparable with that achieved with the use of the lateral window approach, while maintaining the advantage of the less invasive transalveolar approach (Kher et al., 2014). The procedure is effective even in highly resorbed residual ridges, as significant quantities of grafting material can be rapidly introduced at the site with minimum risk of perforation. In general, the transalveolar sinus lift approach is employed for sites with more than 6 mm of bone height pre-operatively, while lateral window approaches are reserved for cases with diminished baseline dimensions (Romero-Millan et al., 2012). The currently proposed technique extends the application of the transalveolar approach to cases with significantly less bone height (3–6 mm).

In this prospective study, a simplified minimally invasive transalveolar technique for sinus augmentation was utilized by exploiting the viscous consistency and flow characteristics of a new generation putty graft. The presented technique serves a dual purpose: to minimize adverse events associated with the use of osteotomes, and to provide an inexpensive technique for predictable elevation of the sinus membrane. A key determinant of success in the present study was careful case selection. On a patient level, only healthy individuals that were non-smokers were admitted to this study in order to avoid poor responders to treatment. On a site-level, none of the cases had sinus septa in the selected implantation regions that may increase the risk of membrane perforation, or technique failure. In such an unfortunate instance, a conventional lateral-window sinus augmentation approach should be utilized to allow for increased visibility, isolation of the membrane perforation and coverage of the perforation with an absorbable collagen

membrane or a platelet-rich-fibrin membrane (Ding et al., 2013; Gassling et al., 2013).

The consistency of the putty helps minimize membrane perforations and associated adverse events during percussion with osteotomes. The technique also attempts to overcome the need to purchase the specialized equipment required to apply hydraulic pressure for the elevation of the schneiderian membrane, while simultaneously placing an adequate volume of the graft material in the site to allow for placement of the implants. Additional advantages of this technique are its atraumatic nature, reduced chair-side times, reduced overall treatment duration, improved patient comfort and minimal graft wastage. The alloplastic biomaterial utilized has been shown to exhibit timely resorption and subsequent replacement with new vital bone in histological studies with residual graft fractions ranging from 4.3% to 11.5%, after 6 months of healing (Mahesh et al., 2012; Kotsakis et al., 2014b). The prompt bone turnover rate observed with CPS putty may provide a clinical benefit in terms of primary and secondary implant stability that increases its suitability in implant surgery (Kotsakis et al., 2014a).

Limitations of the technique proposed, are the necessary operator skill and experience needed for success, and the minimum 3 mm of available bone height needed for achieving primary stability for the implant. In one case where treatment was planned with the recommended technique and a baseline bone height of 2.5 mm, adequate primary stability was not attainable due to the poor bone quality of the site and thus treatment was performed in a staged manner. Therefore, when considering the loosely packed medullary bone frequently encountered in the posterior maxilla, the simplified minimally invasive antral membrane elevation technique should be recommended for sites with at least 3 mm of residual bone height. The application of this technique should always be performed simultaneously with the placement of the appropriate biomaterials in the osteotomy, as the use of a blood clot or platelet concentrates alone may lead to unpredictable results (Jeong et al., 2014). On the other hand, bone substitutes such as freeze-dried allografts, xenografts and mineralized alloplastic substitutes have all shown to be efficacious in sinus augmentation procedures with results comparable to those observed with particulated or block grafts of autogenous bone (Acocella et al., 2011; Chaves et al., 2012; Kher et al., 2014; Sakka and Krenkel, 2011; Sbordone et al., 2014). The use of bone morphogenetic protein 2 has also shown very promising results in sinus augmentation surgery and if the currently available information is supported by longitudinal studies, their clinical use may surpass that of bone substitutes (Gutwald et al., 2010; Triplett et al., 2009).

The presented technique may offer a more conservative procedure with less postoperative morbidity, than the direct sinus augmentation approach. This technique can be successfully used for sinus augmentation with simultaneous implant placement, as it may offer increased primary stability to the implant due to the viscous nature of the utilized bone graft. These advantages make this simplified approach a viable option for transalveolar sinus augmentation. A possible limitation of the present study is the relatively short-term follow-up observed, with a minimum observation time of 9 months when loading was considered the baseline and 12 months when placement was set as the baseline. Nonetheless, it is well established that the vast majority of early and medium-term implant failures occur at the time of second stage surgery rather than manifesting as failure to maintain osseointegration post-loading (Wagenberg and Froum, 2006). Yet, controlled clinical studies are required to longitudinally assess the efficacy of this surgical improvisation in comparison to direct sinus augmentation approaches and to unequivocally prove the proposed superiority of the presented technique on patient-related outcomes.

## 5. Conclusions

The simplified minimally invasive antral membrane elevation technique is based on the application of hydraulic pressure by a viscous bone graft that acts as an incompressible fluid. Therefore, simultaneously with the atraumatic elevation of the schneiderian membrane, grafting of the maxillary sinus is achieved resulting in promotion of intrasinus bone formation, increased implant stability due to the viscoelastic nature of CPS putty, and a shorter operative time owing to the simultaneous elevation and grafting approach. The proposed technique is a simple, efficacious, minimally invasive approach for sinus elevation that can be recommended for sites with at least 3 mm of residual height.

## Conflict of interest

None of the authors has any conflicts of interest to this study.

## References

- Acocella A, Bertolai R, Nissari J, Sacco R: Clinical, histological and histomorphometric study of maxillary sinus augmentation using cortico-cancellous fresh frozen bone chips. *J Craniomaxillofac Surg* 39(3): 192–199, Apr 2011
- Chaves MD, de Souza Nunes LS, de Oliveira RV, Holgado LA, Filho HN, Matsumoto MA, et al: Bovine hydroxyapatite (Bio-Oss®) induces osteocalcin, RANK-L and osteoprotegerin expression in sinus lift of rabbits. *J Craniomaxillofac Surg* 40(8): e315–e320, Dec 2012
- Cochran DL, Buser D, ten Bruggenkate CM, Weingart D, Taylor TM, Bernard JP, et al: The use of reduced healing times on ITI implants with a sandblasted and acid-etched (SLA) surface: early results from clinical trials on ITI SLA implants. *Clin Oral Implants Res* 13: 144–153, 2002
- Dahlin C, Johansson A: Iliac crest autogenous bone graft versus alloplastic graft and guided bone regeneration in the reconstruction of atrophic maxillae: a 5-year retrospective study on cost-effectiveness and clinical outcome. *Clin Implant Dent Relat Res* 13: 305–310, 2011
- Del Fabbro M, Corbella S, Weinstein T, Ceresoli V, Taschieri S: Implant survival rates after osteotome-mediated maxillary sinus augmentation: a systematic review. *Clin Implant Dent Relat Res* 14(Suppl. 1): e159–168, 2012
- Del Fabbro M, Testori T, Francetti L, Weinstein R: Systematic review of survival rates for implants placed in the grafted maxillary sinus. *Int J Periodontics Restorative Dent* 24: 565–577, 2004
- Ding X, Zhu XH, Wang HM, Zhang XH: Effect of sinus membrane perforation on the survival of implants placed in combination with osteotome sinus floor elevation. *J Craniofac Surg* 24(2): e102–104, 2013
- Engelke W, Deckwer I: Endoscopically controlled sinus floor augmentation. A preliminary report. *Clin Oral Implants Res* 8: 527–531, 1997
- Ferrigno N, Laureti M, Fanali S: Dental implants placement in conjunction with osteotome sinus floor elevation: a 12-year life-table analysis from a prospective study on 588 ITI implants. *Clin Oral Implants Res* 17: 194–205, 2006
- Galindo-Moreno P, Avila G, Fernandez-Barbero JE, Mesa F, O'Valle-Ravassa F, Wang HL: Clinical and histologic comparison of two different composite grafts for sinus augmentation: a pilot clinical trial. *Clin Oral Implants Res* 19: 755–759, 2008
- Gassling V, Purcz N, Braesen JH, Will M, Gierloff M, Behrens E, et al: Comparison of two different absorbable membranes for the coverage of lateral osteotomy sites in maxillary sinus augmentation: a preliminary study. *J Craniomaxillofac Surg* 41(1): 76–82, Jan 2013
- Gutwald R, Haberstroh J, Stricker A, Rütger E, Otto F, Xavier SP, et al: Influence of rhBMP-2 on bone formation and osseointegration in different implant systems after sinus-floor elevation. An in vivo study on sheep. *J Craniomaxillofac Surg* 38(8): 571–579, Dec 2010
- Hartlev J, Kohberg P, Ahlmann S, Andersen NT, Schou S, Isidor F: Patient satisfaction and esthetic outcome after immediate placement and provisionalization of single-tooth implants involving a definitive individual abutment. *Clin Oral Implants Res*, 2013 (Epub ahead of print)
- Jeong SM, Lee CU, Son JS, Oh JH, Fang Y, Choi BH: Simultaneous sinus lift and implantation using platelet-rich fibrin as sole grafting material. *J Craniomaxillofac Surg*, 2014 (Epub ahead of print)
- Kfir E, Goldstein M, Rafaelov R, Yerushalmi I, Kfir V, Mazor Z, et al: Minimally invasive antral membrane balloon elevation in the presence of antral septa: a report of 26 procedures. *J Oral Implantol* 35: 257–267, 2009a
- Kfir E, Goldstein M, Yerushalmi I, Rafaelov R, Mazor Z, Kfir V, et al: Minimally invasive antral membrane balloon elevation – results of a multicenter registry. *Clin Implant Dent Relat Res* 11(Suppl. 1): e83–e91, 2009b
- Kfir E, Kfir V, Eliav E, Kaluski E: Minimally invasive antral membrane balloon elevation: report of 36 procedures. *J Periodontol* 78: 2032–2035, 2007
- Kfir E, Kfir V, Goldstein M, Mazor Z, Kaluski E: Minimally invasive subnasal elevation and antral membrane balloon elevation along with bone augmentation and implants placement. *J Oral Implantol* 38: 365–376, 2012
- Kfir E, Kfir V, Kaluski E, Mazor Z, Goldstein M: Minimally invasive antral membrane balloon elevation for single-tooth implant placement. *Quintessence Int* 42: 645–650, 2011
- Kfir E, Kfir V, Mijiritsky E, Rafaelov R, Kaluski E: Minimally invasive antral membrane balloon elevation followed by maxillary bone augmentation and implant fixation. *J Oral Implantol* 32: 26–33, 2006
- Kher U, Mazor Z, Stanitsas P, Kotsakis GA: Implants placed simultaneously with lateral window sinus augmentation using a putty alloplastic bone substitute for increased primary implant stability: a retrospective study. *Implant Dent* 23: 496–501, 2014
- Kotsakis G, Chrepa V, Marcou N, Prasad H, Hinrichs J: Flapless alveolar ridge preservation utilizing the 'socket-plug' technique: clinical technique and review of the literature. *J Oral Implantol*, 2012 (in press)
- Kotsakis GA, Salama M, Chrepa V, Hinrichs JE, Gaillard P: A randomized, blinded, controlled clinical study of particulate anorganic bovine bone mineral and calcium phosphosilicate putty bone substitutes for socket preservation. *Int J Oral Maxillofac Implants* 29: 141–151, 2014a
- Kotsakis GA, Joachim F, Saroff SA, Mahesh L, Prasad H, Rohrer M: Histomorphometric evaluation of a calcium-phosphosilicate bone substitute in extraction sockets. *Int J Periodontics Restorative Dent* 34: 233–239, 2014b
- Mahesh L, Salama MA, Kurtzman GM, Joachim FP: Socket grafting with calcium phosphosilicate alloplast putty: a histomorphometric evaluation. *Compend Contin Educ Dent* 33: e109–e115, 2012
- Mazor Z, Ioannou A, Venkataraman N, Kotsakis G: A minimally invasive sinus augmentation technique using a novel bone graft delivery system. *Int J Oral Implantol Clin Res* 4: 78–82, 2013
- Mazor Z, Kfir E, Lorean A, Mijiritsky E, Horowitz RA: Flapless approach to maxillary sinus augmentation using minimally invasive antral membrane balloon elevation. *Implant Dent* 20: 434–438, 2011
- Mazor Z, Peleg M, Gross M: Sinus augmentation for single-tooth replacement in the posterior maxilla: a 3-year follow-up clinical report. *Int J Oral Maxillofac Implants* 14: 55–60, 1999
- Nickenie HJ, Wichmann M, Zöller JE, Eitner S: 3-D based minimally invasive one-stage lateral sinus elevation – a prospective randomized clinical pilot study with blinded assessment of postoperative visible facial soft tissue volume changes. *J Craniomaxillofac Surg*, 2014 (Epub ahead of print)
- Nkenke E, Schlegel A, Schultze-Mosgau S, Neukam FW, Wiltfang J: The endoscopically controlled osteotome sinus floor elevation: a preliminary prospective study. *Int J Oral Maxillofac Implants* 17: 557–566, 2002
- Romero-Millan J, Martorell-Calatayud L, Penarrocha M, Garcia-Mira B: Indirect osteotome maxillary sinus floor elevation: an update. *J Oral Implantol* 38(6): 799–804, 2012
- Rothamel D, Wahl G, d'Hoedt B, Nentwig GH, Schwarz F, Becker J: Incidence and predictive factors for perforation of the maxillary antrum in operations to remove upper wisdom teeth: prospective multicentre study. *Br J Oral Maxillofac Surg* 45(5): 387–391, Jul 2007
- Sakka S, Krenkel C: Simultaneous maxillary sinus lifting and implant placement with autogenous parietal bone graft: outcome of 17 cases. *J Craniomaxillofac Surg* 39(3): 187–191, Apr 2011
- Sbordone C, Toti P, Guidetti F, Califano L, Pannone G, Sbordone L: Volumetric changes after sinus augmentation using blocks of autogenous iliac bone or freeze-dried allogeneic bone. A non-randomized study. *J Craniomaxillofac Surg* 42(2): 113–118, Mar 2014
- Scheuber S, Hicklin S, Bragger U: Implants versus short-span fixed bridges: survival, complications, patients' benefits. A systematic review on economic aspects. *Clin Oral Implants Res* 23(Suppl. 6): 50–62, 2012
- Summers RB: A new concept in maxillary implant surgery: the osteotome technique. *Compendium* 15(152): 54–56, 1994
- Sununliganon L, Peng L, Singhatanadgit W, Cheung LK: Osteogenic efficacy of bone marrow concentrate in rabbit maxillary sinus grafting. *J Craniomaxillofac Surg*, 2014 (Epub ahead of print)
- Triplett RG, Nevins M, Marx RE, Spagnoli DB, Oates TW, Moy PK, et al: Pivotal, randomized, parallel evaluation of recombinant human bone morphogenetic protein-2/absorbable collagen sponge and autogenous bone graft for maxillary sinus floor augmentation. *J Oral Maxillofac Surg* 67(9): 1947–1960, Sep 2009
- Vance GS, Greenwell H, Miller RL, Hill M, Johnston H, Scheetz JP: Comparison of an allograft in an experimental putty carrier and a bovine-derived xenograft used in ridge preservation: a clinical and histologic study in humans. *Int J Oral Maxillofac Implants* 19: 491–497, 2004
- Wagenberg B, Froum SJ: A retrospective study of 1925 consecutively placed immediate implants from 1988 to 2004. *Int J Oral Maxillofac Implants* 21(1): 71–80, 2006
- Xuan F, Lee CU, Son JS, Jeong SM, Choi BH: A comparative study of the regenerative effect of sinus bone grafting with platelet-rich fibrin-mixed Bio-Oss® and commercial fibrin-mixed Bio-Oss®: an experimental study. *J Craniomaxillofac Surg* 42(4): e47–e50, Jun 2014